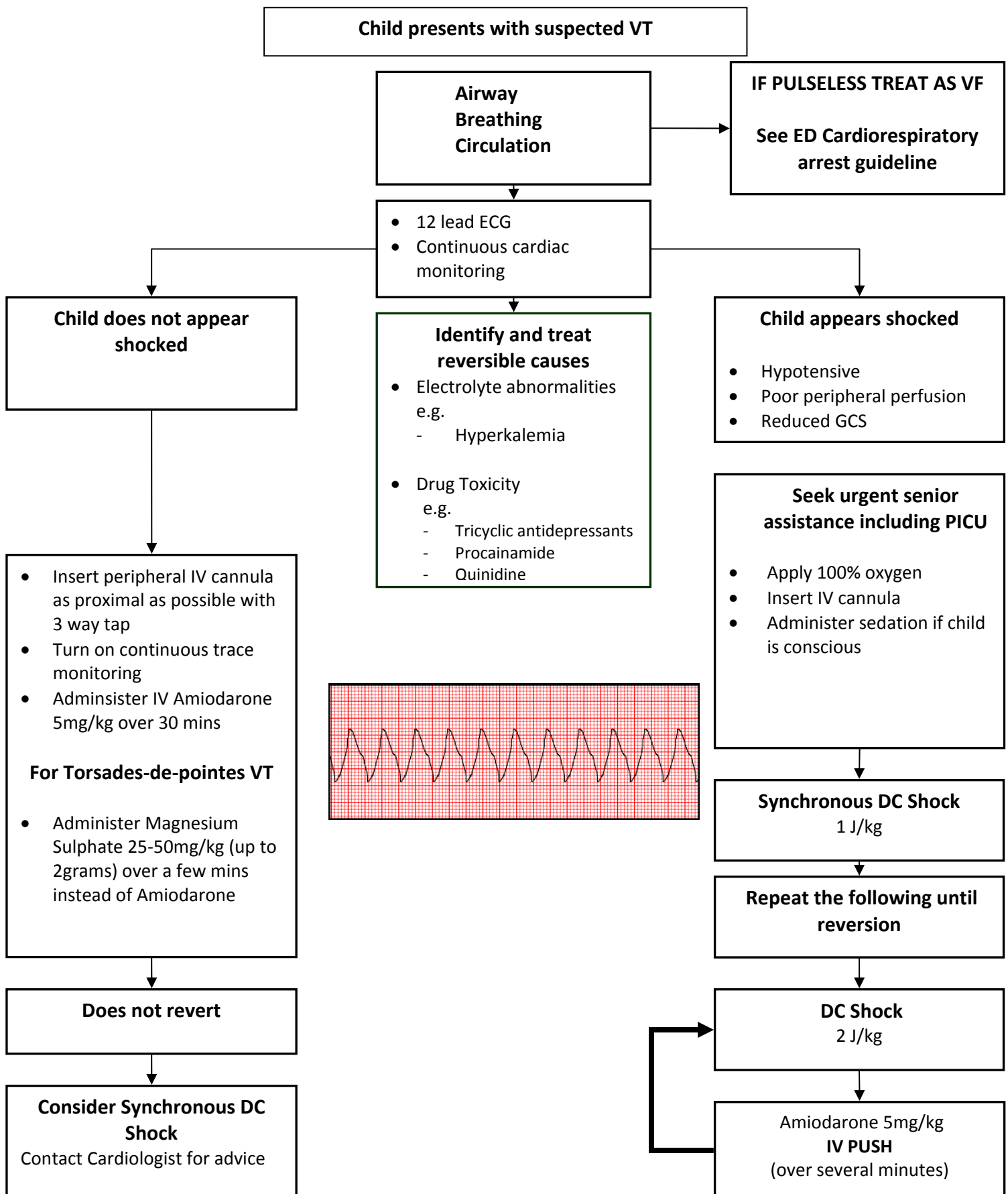


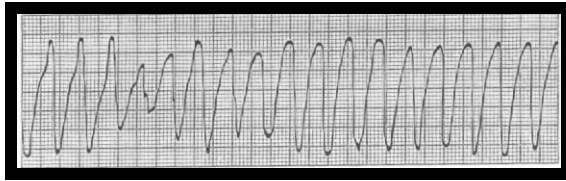
Ventricular Tachycardia

Management Guidelines
 Emergency Department
 Princess Margaret Hospital for Children
 Perth, Western Australia
 Reviewed January 2011
 M Borland
 Updated February 2013
 D Speldewinde and M Borland

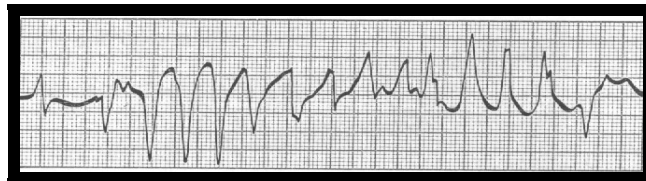

VT

- **VT** is extremely rare in children.



- **Polymorphic VT (Torsade)** occurs in long QT syndrome and some drugs (see table above) – these patients rarely present in VT – generally arrest outside the hospital and are resuscitated to sinus rhythm or not.



- VT rarely occurs in patients with abnormal cardiac structure or function (in which case a history is usually available), though SVT is still more common.
- Paediatric VT can occur in structurally normal hearts, but generally patients present with palpitations and are rarely haemodynamically compromised.